

Impact of mesh fixation vs non-fixation in laparoscopic transabdominal preperitoneal inguinal hernia repair on chronic groin pain and quality of life: a prospective randomized study

Mohamed E. Zayed, Mohamed S. Essa

Department of General Surgery, Benha University Hospital, Faculty of Medicine, Benha University, Benha, Egypt

Correspondence to Mohamed E. Zayed, MD, Department of General Surgery, Faculty of Medicine, Benha University, Benha, 13511, Egypt. Tel: +20 111 024 3330; e-mail: drmohamedelsaid1983@gmail.com

Received: 19 January 2020

Revised: 27 January 2020

Accepted: 16 February 2020

Published: 28 August 2020

The Egyptian Journal of Surgery 2020, 39:574–581

Aim

A randomized controlled study comparing the impact of fixation vs non-fixation of mesh in laparoscopic transabdominal preperitoneal (TAPP) inguinal hernioplasty on chronic groin pain and quality of life of patients.

Patients and methods

This study includes 100 patients presented with primary unilateral indirect inguinal hernia treated at Benha University Hospital from June 2016 to August 2018. Patients were randomized to TAPP inguinal hernia repair with fixation of mesh (group A, $n=50$) and without fixation of mesh (group B, $n=50$). Parameters assessed included operative duration, time to early ambulation, postoperative pain, and postoperative complications and quality of life. Assessment of pain was done using the visual analog scale at 1 day, 3 months, and 6 months after surgery. Evaluation of quality of life was done using the 36-item short-form health survey 3 months postoperatively.

Results

The mean operative duration and time to early ambulation in group B (without mesh fixation) were reduced significantly in comparison to group A (with mesh fixation). The visual analog scale score at 1 day, 3 months, and 6 months after surgery for group B was significantly lower than in group A. The physical function (PF), bodily pain (BP), role physical (RP), and general health (GH) in group B were significantly higher than group A while there is no statistically significant difference in vitality (VT), role emotional (RE), social function (SF), and mental health (MH) between group A and group B.

Conclusion

Mesh fixation and non-fixation in laparoscopic TAPP approach for the repair of inguinal hernia are comparable regarding operative duration, postoperative complications, and time to ambulation while pain scores and quality of life were significantly better in the non-fixation group.

Keywords:

fixation, inguinal hernia repair, mesh, non-fixation, postoperative pain, quality of life, transabdominal preperitoneal

Egyptian J Surgery 39:574–581

© 2020 The Egyptian Journal of Surgery

1110-1121

Introduction

Repair of inguinal hernia is one of the oldest and most common operations. The National Center for Health Statistics show that about 750 000 groin herniorrhaphies are performed annually in the USA. More than 80% of these herniorrhaphies use mesh prosthesis and most of the patients are operated on an outpatient basis [1].

Laparoscopic inguinal hernioplasty have been established to be effective and safe, with minimal postoperative groin pain, less use of analgesia, and faster return to daily normal activity [2].

There are two common approaches for laparoscopic inguinal hernia repair, the first one is the transabdominal preperitoneal (TAPP) approach and the second one is a totally extraperitoneal approach.

Both of them apply the mesh in the preperitoneal space [3].

Both approaches have potential advantages, such as decreased pain after surgery, rapid recovery, and faster return to normal functional status. However, the advantages are not invariably realized; a laparoscopic approach is not always considered minimally invasive because of several disadvantages such as the current use of general anesthesia, the need to traverse the peritoneal cavity in the TAPP technique with

This is an open access journal, and articles are distributed under the terms of the Creative Commons Attribution-NonCommercial-ShareAlike 4.0 License, which allows others to remix, tweak, and build upon the work non-commercially, as long as appropriate credit is given and the new creations are licensed under the identical terms.

increased risk of bowel injury, and the increase in operative time and financial costs [4].

There are rare reports that described the complications related to the application of tackers used for mesh fixation such as postoperative adhesions, chronic pain, bowel obstruction, and risk of bowel and urinary bladder perforation [5].

Development of different complications following laparoscopic inguinal hernioplasty such as postoperative neuralgia, meralgia paresthetica due to lateral cutaneous nerve of the thigh entrapment, or periostitis can be prohibited by avoidance of mesh fixation. Once the mesh is fixed by the fibrous tissue, recurrences will only develop if the position of the mesh is not corrected anatomically, if the size of the abdominal wall defect is large in relation to the size of the mesh (the mesh will be cracked from the abdominal wall) or if another abdominal wall defect exists next to the mesh [6].

Mesh fixation vs non-fixation is still a controversy in laparoscopic inguinal hernia repair via TAPP approach. Till now, it is not known whether fixation of the mesh affects the rate of recurrence and incidence of postoperative neuralgia [7]. The aim of our study was to compare mesh fixation with non-fixation regarding life quality and chronic pain.

Patients and methods

The ethical rules of human medical research of Helsinki, 7th revision (2013) were applied with an informed consent from each patient after clear explanation of the study elements was fulfilled.

This is prospective randomized controlled study. It includes 100 adult male patients who underwent laparoscopic TAPP primary unilateral oblique inguinal hernia. The study was accomplished between June 2016 and August 2018 at the General Surgery Department, Benha University Hospitals, Egypt. All patients were followed up for 1 year, till August 2019. One hundred patients were blindly randomized into two groups: group A included 50 hernias which were repaired with mesh fixation and group B included 50 hernias which were repaired without mesh fixation.

Inclusion criteria

Adult patients with age more than 18 years presented with primary unilateral oblique inguinal hernia.

Exclusion criteria

The following patients were excluded:

- (1) Age less than 18 years.
- (2) Recurrent inguinal hernia.
- (3) Complicated hernia.
- (4) Huge scrotal hernia.
- (5) Previous lower abdominal surgery.
- (6) Pelvic surgery.
- (7) Bad general condition.

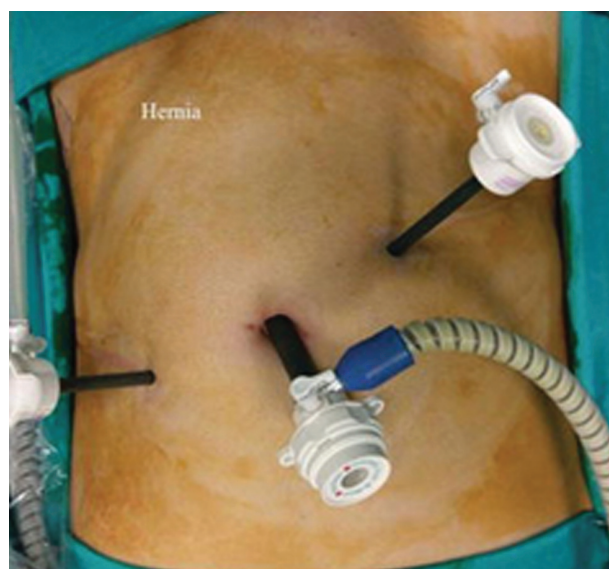Preoperative evaluation included complete blood count, coagulation profile, liver function tests, renal panel, fasting blood glucose, ECG, and chest radiograph. Patients were asked to fast 8 h before surgery.

Operative technique

On the operating table, the patient is placed in the supine position; the arms of the patient are tucked on each side of the patient to facilitate access. After administration of general anesthesia, Foley catheter is inserted; a routine scrubbing is performed to include entire abdominal wall, upper thigh, penis, and scrotum. A 10-mm umbilical port was inserted.

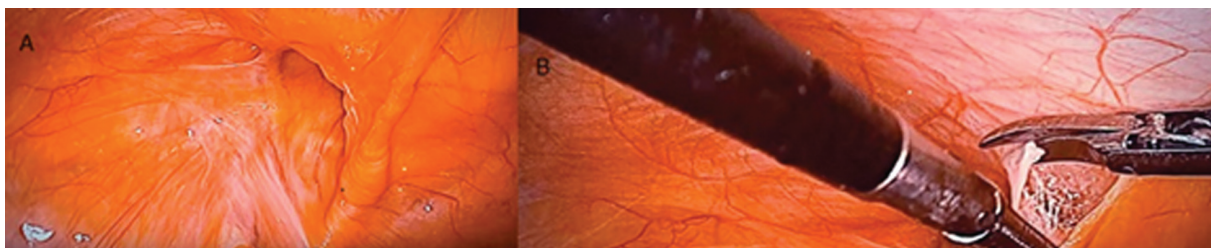
Pneumoperitoneum was created by carbon dioxide with pressure set at 14 mmHg. A 10-mm port and a 5-mm port are inserted on the contralateral and ipsilateral side of the hernia, at the level of the umbilicus and lateral to the rectus sheath, respectively (Fig. 1). After identification of the hernial sac, peritoneal incision was made starting

Figure 1



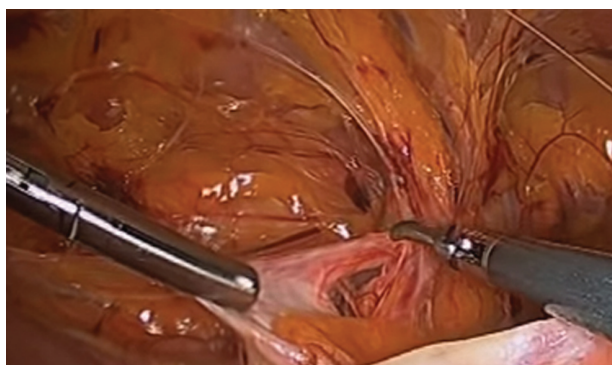Trocar sites.

Figure 2



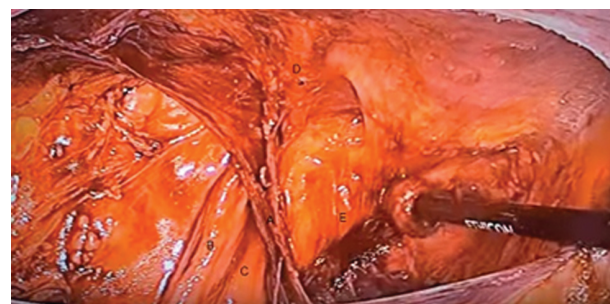Hernia sac at the internal ring (a) with peritoneal incision for creation of peritoneal flaps (b).

Figure 3



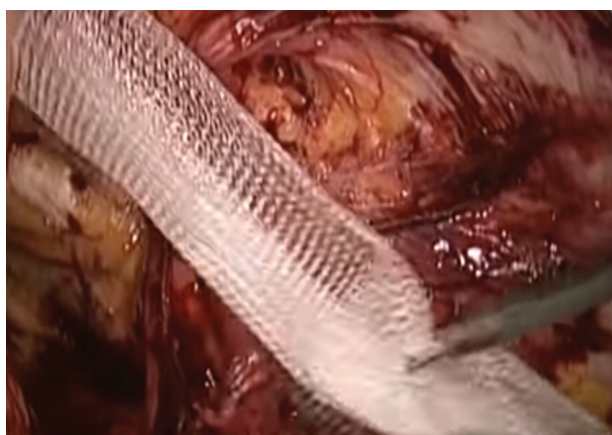Reduction of hernial sac.

Figure 4



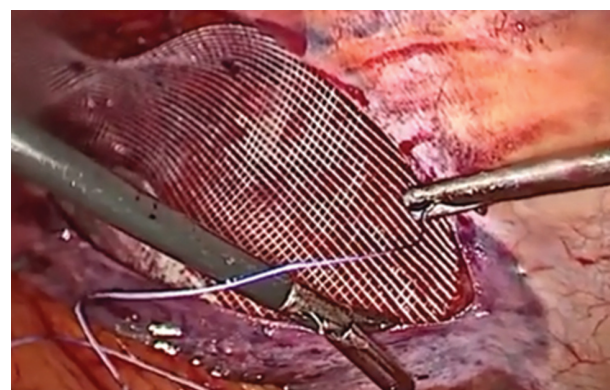
Anatomical structures in the preperitoneal space: (a) vas, (b) spermatic vessels, (c) triangle of doom, (d) inferior epigastric vessels, and (e) Cooper's ligament.

Figure 5



Insertion of mesh in the preperitoneal space.

Figure 6



Group A, fixation of mesh with tackers with closure of peritoneal flaps.

above the anterior superior iliac spine till the medial umbilical ligament with elevation of the peritoneal flaps using hook, laparoscopic scissor, or harmonic scalpel (Fig. 2). The sac was dissected and reduced (Fig. 3). Preperitoneal space was created by careful dissection of the adipose tissue to expose pubic ramus and Cooper's ligament. Adequate dissection of the preperitoneal retropubic tissue permits easier positioning and proper flattening of the mesh. To ensure mesh flattening, the medial border of the

mesh should be at symphysis pubis, medial inferior border 3 cm below Cooper's (pectineal) ligament, lateral border at psoas major muscle and anterior superior iliac spine, upper limit at least 3 cm above the conjoined tendon, and lateral inferior border to allow spermatic cord peritonealization (6–8 cm isolation of the hernia sac and spermatic cord) (Fig. 4). The mesh (Prolene mesh) was applied of size 10×15 cm (Fig. 5); the mesh should cover the internal ring, inferior epigastric vessels, and medial compartment to prevent recurrence. In the mesh fixation group, the mesh was fixed using tackers (ProTack) to the

Figure 7



Group B, application of mesh without fixation.

pectineal ligament, medial and lateral to inferior epigastric vessels (Fig. 6). In mesh non-fixation group, the mesh was not fixed (Fig. 7). Closure of the peritoneal flaps was done using absorbable sutures (Vicryl 2/0) in a continuous manner.

Postoperative care

All patients were admitted for at least 24 h after surgery. The patients were discharged after tolerating diet, passing bowel motion, fully mobile, and after pain was controlled by oral analgesia. Any complication was reported and managed.

Follow-up

The patients were followed up for at least 1 year.

Parameters assessed

- (1) Operative time.
- (2) Time to ambulation.
- (3) Postoperative pain.

The pain was evaluated by the visual analog score (VAS) at 1 day, 3 months, and 6 months after surgery. The VAS scoring is zero (no pain), 1–3 (mild pain), 4–6 (moderate pain), and 7–10 (severe pain). Chronic pain was considered if the pain duration is more than 3 months [8].

Postoperative complications

- (1) Wound infection.
- (2) Postoperative seroma.
- (3) Postoperative hematoma.
- (4) Foreign body sensation.
- (5) Recurrence.

Quality of life

The Medical Outcomes Study 36-item Short-Form (MOSSF36) Health Survey invented by Stewart [9] which is formed of eight perspectives was used for the

evaluation of quality of life: general health (GH), role physical (RP), physical functions (PF), bodily pain (BP), role emotional (RE), social functions (SF), vitality (VT), and mental health (MH). Quality of life evaluation was completed three months after surgery through phone call and written record.

Statistical analysis

Measurement data were expressed as mean±SD and data were analyzed using Student's *t*-test. Count data were analyzed using the χ^2 -test. All data were processed with an SPSS 17.0 software package. All statistical calculations were done using computer program IBM SPSS (Statistical Package for the Social Science; IBM Corp, Armonk, NY, USA) release 22 for Microsoft Windows. A *P* less than 0.05 was considered significant statistically.

Results

This study involved 100 patients presented with unilateral primary indirect inguinal hernia randomized into two groups. Group A (the mesh fixation group) included 50 patients (35 right sided and 15 left sided) and group B (mesh non-fixation group) included 50 patients (20 right sided and 30 left sided).

All patients were men. There was no any statistically significant differences between the two groups regarding age ($P=0.35$), mean diameter of hernia ($P=0.81$), preoperative VAS ($P=0.76$) or BMI ($P=0.66$). The mean operative time (70.5 ± 11.2 vs 60.2 ± 9.3 , $P<0.05$) and postoperative time to ambulation (29.4 ± 7.0 vs 25.5 ± 6.0 , $P<0.05$) of group B were all reduced significantly in comparison to group A (Table 1). Before surgery there was no significant difference between the two groups regarding the quality of life using SF-36 health survey scores (GH, BP, RP, PF, RF, SF, VT, and MH) (Table 2).

Follow-up period showed no significant difference between the two groups, for group A it was 12.3 months) while in group B it was 12.7 months. Postoperative complications, after 1 week six (12%) and five (10%) patients in group A and group B developed seroma, respectively; only two patients in group A (4%) developed seroma 1 month postoperatively while group B showed no seroma formation after 1 month. There is no postoperative seroma in both groups after 3 months. Scrotal hematoma developed in five patients in group A and four patients in group B 1 week postoperatively which resolved spontaneously after 1 month. There was no

Table 1 Demographics and operative data of the patients

	Group A: with mesh fixation (n=50) [mean±SD (range)]	Group B: without mesh fixation (n=50) [mean ±SD (range)]	P value
Sex (male/female)	50/0	50/0	0.86
Age (years)	43.5±11.8 (20–77)	42.6±13.1 (20–79)	0.35
Preoperative VAS	0.7±0.02 (0.5–2.0)	0.8±0.05 (0.5–3.3)	0.76
BMI (kg/m ²)	25.7±5.1 (20.2–33.2)	25.0±5.3 (20.7–35.1)	0.66
Mean diameter of defect (cm)	2.4±0.9 (1.0–3.7)	2.5±0.6 (1.0–3.5)	0.81
Operative duration (min)	70.5±11.2 (50–90)	60.2±9.3 (50–90)	0.02
Postoperative time to ambulation (h)	29.4±7.0 (21–37)	25.5±6.0 (20–36)	0.02

VAS, visual analog scale.

Table 2 Preoperative MOSSF-36 health survey scores between the two groups

	Mean±SD (range)		P value
	Group A: fixation group (n=50)	Group B: non-fixation group (n=50)	
General health (GH)	74±9	75±11	0.36
Bodily pain (BP)	73±10	74±11	0.54
Role physical (RP)	80±8	81±9	0.73
Physical functions (PF)	79±16	81±15	0.58
Role emotional (RE)	79±11	78±12	0.45
Social functions (SF)	77±13	79±11	0.54
Vitality (VT)	73±14	75±13	0.74
Mental health (MH)	77±9	79±11	0.65

Table 3 Incidence of complications in both groups

	Group A: fixation group [n (%)]	Group B: non-fixation group [n (%)]	P value
Wound infection	0	0	NS
Seroma			
1 week	6 (12)	5 (10)	0.79
1 month	2 (4)	0	NS
3 month	0	0	NS
Scrotal hematoma (1 week postoperatively)	5 (10)	4 (8)	0.78
Follow-up (months)	12.3±2.8	12.7±3.5	0.9
Recurrence rate	0	0	NS
Foreign body sensation	8 (16)	7 (14)	0.78

Table 4 Postoperative pain scores in both groups

Time	Mean±SD (range)		P value
	Group A: with mesh fixation (n=50)	Group B: without mesh fixation (n=50)	
24 h	5.4±0.9 (3–9)	4.7±0.5 (3–9)	0.03
3 months	2±0.6 (0–6)	0.9±0.4 (0–5)	0.02
6 months	1.0±0.1 (0–3)	0.8±0.3 (0–2)	<0.01

significant difference in postoperative scrotal hematoma between two groups ($P>0.05$). Eight patients (16%) from group A and seven patients (14%) from group B had foreign body sensation in the inguinal region ($P>0.05$). Furthermore, during the follow-up period, there is no evidence of recurrence or wound infection in both groups of patients (Table 3).

VAS was used for postoperative pain evaluation for all patients. In group B, postoperative VAS scores at day

1, 3 months, and 6 months were all significantly lower than those in group A ($P<0.05$) (Table 4).

The MOSSF-36 Health Survey was used for evaluation of quality of life 3 months after surgery. In group B, GH, BP, RP, and PF scores were significantly higher in comparison to group A ($P<0.05$) while RE, SF, VT, and MH scores showed no significant difference between the two groups ($P>0.05$) (Table 5).

Table 5 Comparison of postoperative MOSSF-36 Health Survey scores between the two groups

	Mean±SD (range)		P value
	Group A: with mesh fixation (n=50)	Group B: without mesh fixation group (n=50)	
General health (GH)	70±11	80±12	0.04
Bodily pain (BP)	73±10	82±12	0.03
Role physical (RP)	77±9	85±11	0.02
Physical functions (PF)	81±9	85±6	0.04
Role emotional (RE)	77±12	78±10	0.37
Social functions (SF)	79±8	78±12	0.27
Vitality (VT)	73±14	74±15	0.35
Mental health (MH)	77±9	79±11	0.56

Table 6 Comparative data for recurrence

References	Number of hernia repairs	% recurrence
Khazanchee <i>et al.</i> [19]	105	2.9
Beattie <i>et al.</i> [17]	89	Nil
Tamme <i>et al.</i> [20]	5203	2.6
Cocks <i>et al.</i> [21]	148	4
Ferzli <i>et al.</i> [22]	50	Nil
This study	100	Nil

Discussion

Inguinal hernia repair is one of the most common elective general surgery operations. The first laparoscopic technique is described by Ger in 1982; various technical modifications have been done in both laparoscopic and open inguinal hernioplasty aiming for a decreased rate of recurrence [10].

Several methods have been used for mesh fixation in the laparoscopic repair of inguinal hernia, including staples, tackers, sutures, and polycyanoacrylate derivatives. Neuropathic complications are more common with the use of staples or tackers. The prevalence of such complications is 0–3% in the case of inguinal hernioplasty for primary hernia and increases to 5.7% with the repair of recurrent inguinal hernia [11].

Recurrence rates of 2% or less are now routinely reported from specialty centers performing either laparoscopic or conventional tension-free repairs of inguinal hernia.

The recurrence rate after laparoscopic TAPP approach for inguinal hernia repair is 1–4.3% [12,13]. Several theories responsible for recurrence of hernia has been suggested. Deans *et al.* [14] described that rolling of the mesh away from the pubic ramus with exposure of Hesselbach's triangle is responsible for medial recurrence.

Fiennes and Taylor suggested that abdominal desufflation after laparoscopic inguinal hernia

repair elevates the lower edge of the mesh which leads to migration of the inferomedial aspect from the Cave of Retzius in the presence of a direct defect [15,16].

Inadequate dissection of the myopectineal orifice and improper size of the mesh are the two most common causes of inguinal hernia recurrence after hernioplasty. Thirteen videotapes of hernia repair that had recurred in the multicenter trial by Fitzgibbons and colleagues are reviewed by Lowham and colleagues, and found that inadequate dissection of the myopectineal orifice was the main cause of hernia recurrence [13,17].

The Smith *et al.* [18] study included 502 patients with laparoscopic TAPP hernioplasty; the patients were randomly divided into two groups, the mesh fixation group (273 patients) and the nonfixation group (263 patients) hernia with an average follow-up period of 16 months. The study showed no statistically significant variation between the two groups regarding hernia recurrence which is similar to our result and they concluded that mesh fixation is not essential in laparoscopic TAPP approach for the repair of inguinal hernia (Table 6).

Chronic groin pain and quality of life are the essential evaluation components after inguinal hernia repair [23]. VAS is a simple, easy, and effective method for the evaluation of postoperative pain [24], while MOSSF-36 Health Survey is considered an important and effective tool for the assessment of postoperative quality of life [25]. Postoperative chronic pain is considered an essential factor affecting the quality of life after inguinal hernia repair and is usually presented with inguinal or perineal burning sensation in addition to paresthesia in these areas. It also might affect sexual functions. There are many causes of pain after hernioplasty including suturing of mesh in pubic tubercle periosteum which is the most common cause, nerve entrapment due to fibrosis or

ischemia of the spermatic cord, scarring after surgery and nerve injury either by stretching or contusion. Proper surgical procedures such as reduction of suturing and fixation in addition to avoiding nerve and vessels injuries are the main key to prevent post-hernioplasty chronic pain [26,27]. Li *et al.* [28] also conducted a study that included 100 patients who were divided randomly into two groups as in our study and showed that VAS score and life quality is better in the non-fixation group in addition to no significant variation in hernia recurrence between the two groups. Furthermore, our study has shown that inguinal hernia repair without mesh fixation was associated with better postoperative recovery, less operative duration, and decrease in postoperative chronic pain in addition to significant improvement in the quality of life parameters (GH, BP, RP, and PF) which is similar to that described by previous studies [26–28].

The incidence of postoperative scrotal hematoma in our study 1 week after repair (8–10%) in both groups without statistically significant variation is similar to that reported by Li *et al.* [28]. The hematoma disappeared spontaneously in all patients.

It is important to note that repair of inguinal hernia without mesh fixation in the TAPP approach is not recommended in certain situations including large hernias, irreducible hernias, hernias with a defect size of more than 4 cm in diameter, intolerance to general anesthesia, recurrent hernia, and past history of lower abdominal operations because inguinal hernia repair in such situations was associated with surgery failure or hernia recurrence [28]. So, the laparoscopic TAPP approach without mesh fixation should be done for patients presented with primary unilateral oblique inguinal hernia especially if the hernia is small (<4 cm in diameter).

The limitations of study is that only male patients with indirect inguinal hernia with a defect smaller than 4 cm in diameter were included without analysis of hernia subtypes.

Conclusion

Laparoscopic TAPP approach for inguinal hernia repair without mesh fixation is recommended for patients with primary oblique inguinal hernia especially if the size of the defect is less than 4 cm because this approach is associated with less postoperative pain and better quality of life.

Acknowledgements

Mohamed S. Essa contributed to study concept, design, data collection, interpretation, literature review, and writing of the manuscript; Mohamed E. Zayed contributed to literature review and writing of the manuscript.

Financial support and sponsorship

Nil.

Conflicts of interest

There are no conflicts of interest.

References

- Rutkow K. Epidemiologic, economic and sociologic aspects of hernia surgery in the United States in the 1990s. *Surg Clin North Am* 1998; 78:941–951.
- Velanovich V. Laparoscopic versus open surgery a preliminary comparison of quality of life outcomes. *Surg Endosc* 2000; 14:16–21.
- Hanif H, Memon SA. Outcome of laparoscopic totally extraperitoneal hernioplasty for inguinal hernia. *J Ayub Med Coll Abbottabad* 2015; 27:613–616.
- Neumayer L, Giobbie-Hurder A, Jonasson O, Fitzgibbons R Jr., Dunlop D, Gibbs J, *et al.* Open mesh vs laparoscopic mesh repair of inguinal hernia. *Engl J Med* 2004; 350:1819–1827.
- Ladurner R, Mussack T. Small bowel perforation due to protruding spiral tackers: a rare complication in laparoscopic incisional hernia repair. *Surg Endosc* 2004; 18:1001.
- Totté E, Van Hee R, Kox G, Hendrickx L, van Zwieten KJ. Surgical anatomy of the inguinal region: implication during inguinal laparoscopic herniorrhaphy. *Eur Surg Res* 2005; 37:185–190.
- Siddaiah? Subramanya M, Ashrafi D, Memon B, Memon MA. Causes of recurrence in laparoscopic inguinal hernia repair. *Hernia* 2018; 22:975–986.
- Alfieri S, Di Miceli D, Doglietto GB. Prophylactic ilioinguinal neurectomy in open inguinal hernia repair. *Ann Surg* 2007; 245:663.
- Perneger TV, Lepège A, Etter JF, Rougemont A. Validation of a French-language version of the MOS 36-item short form health survey (SF-36) in young healthy adults. *J Clin Epidemiol* 1995; 48:1051–1160.
- Condon RE, Nyhus LM. Complications of groin hernia. In: Condon RE, Nyhus LM, editors. *Hernia*. 4th ed. Philadelphia, PA: JB Lippincott 2010. 269.
- Charalambous MP, Charalambous CP. Incidence of chronic groin pain following open mesh inguinal hernia repair, and effect of elective division of the ilioinguinal nerve: meta-analysis of randomized controlled trials. *Hernia* 2018; 22:401–409.
- Cavazzola LT, Rosen MJ. Laparoscopic versus open inguinal hernia repair. *Surg Clin* 2013; 93:1269–1279.
- Gopal SV, Warriar A. Recurrence after groin hernia repair-revisited. *Int J Surg* 2013; 11:374–377.
- Deans GT, Wilson MS, Royston CM, Brough WA. Recurrent inguinal hernia after laparoscopic repair: possible cause and prevention. *Br J Surg* 1995; 82:539–541.
- Taylor C, Layani L, Liew V, Ghun M, Crampton N, White S. Laparoscopic inguinal hernia repair without mesh fixation, early results of a large randomised clinical trial. *Surg Endosc* 2008; 22:757–762.
- Fiennes AG, Taylor RS. Learning laparoscopic hernia repair: pitfalls and complications among 178 repairs. *Inguinal Hernia* 1994; 20:270–274.
- Beattie DK, Foley RJE, Callam MJ. Future of laparoscopic inguinal hernia surgery. *Br J Surg* 2000; 87:1727–1728.
- Smith AI, Royston CM, Sedman PC. Stapled and nonstapled laparoscopic transabdominal preperitoneal (TAPP) inguinal hernia repair. A prospective randomized trial. *Surg Endosc* 1999; 13:804–806.
- Khajanchee YS, Urbach DR, Swanstrom LL, Hansen PD. Outcomes of laparoscopic herniorrhaphy without fixation of mesh to the abdominal wall. *Surg Endosc* 2001; 15:1102–1107.
- Tamme C, Scheidbach H, Hampe C, Schneider C, Köckerling F. Totally extraperitoneal endoscopic inguinal hernia repair (TEP). *Surg Endosc* 2003; 17:190–195.

- 21 Cocks JR. Laparoscopic inguinal hernioplasty: a comparison between transperitoneal and extraperitoneal techniques. *Aust N Z J Surg* 1998; 68:506–509.
- 22 Ferzli GS, Frezza EE, Pecoraro AM Jr., Ahern KD. *et al.* Prospective randomized study of stapled versus unstapled mesh in laparoscopic preperitoneal inguinal hernia repair. *J Am Coll Surg* 1999; 188:461–465.
- 23 Koning GG, Andeweg CS, Keus F, van Tilburg MW, van Laarhoven CJ, Akkersdijk WL. The transrectus sheath preperitoneal mesh repair for inguinal hernia: technique, rationale, and results of the first 50 cases. *Hernia* 2012; 16:295–299.
- 24 McCarthy M Jr, Chang CH, Pickard AS, Giobbie-Hurder A, Price DD, Jonasson O, *et al.* Visual analog scales for assessing surgical pain. *J Am Coll Surg* 2005; 201:245–252.
- 25 Stewart AL, Hays RD, Ware JE Jr. The MOS short form General Health Survey: reliability and validity in a patient population. *Med Care* 1988; 26:724–735.
- 26 Bittner R, Arregui ME, Bisgaard T, Dudai M, Ferzli GS, Fitzgibbons RJ, *et al.* Guidelines for laparoscopic (TAPP) and endoscopic (TEP) treatment of inguinal hernia [International Endohernia Society (IEHS)]. *Surg Endosc* 2011; 25:2773.
- 27 Bittner R, Montgomery MA, Arregui E, Bansal V, Bingener J, Bisgaard T, *et al.* Update of guidelines on laparoscopic (TAPP) and endoscopic (TEP) treatment of inguinal hernia (International Endohernia Society). *Surg Endosc* 2015; 29:289–321.
- 28 Li W, Sun D, Sun Y, Cen Y, Li S, Xu Q, *et al.* The effect of transabdominalpreperitoneal (TAPP) inguinal hernioplasty on chronic pain and quality of life of patients: mesh fixation versus non-fixation. *Surg Endosc* 2017; 31:4238–4243.